

# New Frontiers in Laser Surgery

Doru T. Alexandrescu, MD,\* and Edward V. Ross, MD<sup>†</sup>

The simultaneous advances in engineering, medicine, and molecular biology have accelerated the pace of introductions of new light-based technologies in dermatology. In this review, the authors examine recent advances in laser surgery as well as peer into the future of energy-based cutaneous medicine. The future landscape of dermatology will almost undoubtedly include (1) noninvasive imaging technologies and (2) improved “destructive” modalities based on real-time feedback from the skin surface.

Semin Cutan Med Surg 31:88-97 © 2012 Elsevier Inc. All rights reserved.

**KEYWORDS** laser, novel, skin, applications, technology, light, radiofrequency

Most commercially viable laser and light-based technologies start out in the “lab” incubator. After refinement and determination of “practicality,” novel lasers and accessories make their way to the exhibitors’ booths and finally the procedure room. What many clinicians do not realize is that few laser innovations that seem reasonably effective and safe in the laboratory are commercialized. Some innovations are cost prohibitive. In other cases, the translation from bench to bedside is derailed by changing clinical needs or supplanted by newer “even better” technologies. In this brief review, we present a potpourri of already established recent devices and principles that might be integrated into future products.

In identifying new frontiers in cutaneous laser surgery, the authors reviewed recently submitted abstracts at national meetings, examined their own research projects, and looked ahead at promising potential applications that might enhance our laser arsenal in the future.

## Alexandrite Laser for Vascular Lesions

Development of the pulsed dye laser (PDL) created a better approach for the treatment of port wine stains (PWS) and a variety of other vascular lesions, but it has significant limita-

tions. PWS seldom clear completely, and deeper lesions have proved difficult to clear. One recent advance in the vascular arena is the newfound use of the alexandrite laser for “medium”-depth lesions (ie, venous lakes), PWS, and even telangiectasia. As this laser is already part of many providers’ laser lineups, its expanded use is logical. The alexandrite laser shows hemoglobin (Hgb) absorption about 2 times that of the neodymium-doped yttrium aluminum garnet (Nd:YAG) laser and melanin absorption about 3 times that of the Nd:YAG laser. Water absorption is less compared with Nd:YAG laser; however, the laser’s optical penetration depth is less than the Nd:YAG laser in bloodless dermis (about one-half). We have noted that the alexandrite laser performs well in pigmented and vascular lesions.<sup>1,2</sup> One concern is the potential for scarring, particularly when the laser is used in darker skin or with inadequate cooling. Because of deeper penetration, the laser creates bulk heating that might require seconds to cool (like the Nd:YAG laser). On the other hand, despite the lower vascular to melanin absorption ratio vs the Nd:YAG laser, we have overall found the alexandrite laser less likely to cause ulcers and atrophic/hypertrophic scar than its 1064-nm counterpart. Part of these less destructive effects might be related to its lower arteriole to venous blood absorption ratio versus the Nd:YAG laser.<sup>3</sup> Kamel<sup>4</sup> reported his use of a long-pulse alexandrite laser to treat bulky vascular malformations. He treated 14 patients with resistant PWS on the face. The alexandrite laser was applied with a fluence of 50-70 J/cm<sup>2</sup>, 1.5 ms, and 8-mm spot diameter with the dynamic cooling device. Two cases of scars were observed in patients after 1 session. Mild-to-moderate PWS lightening was associated in 6 patients and hyperpigmentation in 1 case. The remainder of the patients’ PWS was largely unchanged.

Alexandrite lasers have been used for the treatment of small venous malformations.<sup>5</sup> Venous vascular malforma-

\*Division of Dermatology, San Diego Medical Center, University of California, San Diego, CA.

<sup>†</sup>Division of Dermatology, Scripps Clinic Carmel Valley, San Diego, CA.

*Conflict of Interest Disclosures:* Dr Ross has received honoraria, consulting fees, and research support from Palomar Medical Technologies, Syneron-Candela Corporation, Cutera, Lumenis, and Alma Lasers. Dr Alexandrescu has no conflicts to report.

Address reprint requests to Edward V. Ross, MD, Scripps Health, 3811 Valley Centre Dr S99, San Diego, CA 92130. E-mail: Ross.Edward@scrippshealth.org

tions are congenital lesions consisting of nonproliferative ectatic vascular channels that do not spontaneously involute. In a small trial, McGill and MacKay used the alexandrite laser for intraoral venous vascular malformation. This procedure that did not require local or general anesthesia, is well tolerated by patients, and is easily repeatable. Treatment was performed using a 755-nm Gentlelase alexandrite laser (Candela Corp, Wayland, MA), using a 3-ms pulse duration, an 8-mm spot size, a fluence of 60 J/cm<sup>2</sup>, and an accompanying dynamic cooling device. After only 1 treatment, complete resolution of the venous element of her tongue malformation was noted, with no evidence of recurrence after >2 years of follow-up. The authors concluded that although the alexandrite laser cannot be used as the primary method for treatment of bulky intraoral venous vascular malformation, it is a useful adjunctive modality in combination with sclerotherapy, especially useful in addressing the residual areas.<sup>5</sup>

McDaniel et al treated spider leg veins in 28 patients with variable-sized telangiectasia using a long-pulsed alexandrite laser (LPA) and 5-ms pulses and 5 laser treatment parameters (15 J/cm<sup>2</sup> × 1 pulse, 20 J/cm<sup>2</sup> × 1 pulse, 20 J/cm<sup>2</sup> × 2 pulses, 20 J/cm<sup>2</sup> × 3 pulses, or 30 J/cm<sup>2</sup> × 1 pulse). Patients received 3 treatments at 4-week intervals. Effects of these treatment parameters on various vessel diameters and the therapeutic activity of a combination of laser plus hypertonic saline sclerotherapy were investigated. The optimal treatment parameter for LPA therapy alone was determined to be 20 J/cm<sup>2</sup>, double pulsed at 1 Hz. After 3 treatments at 4-week intervals, subjective grading indicated a 63% reduction in leg telangiectasias. Medium-diameter vessels had the best response, whereas small-vessel diameters responded poorly. The addition of 23.4% hypertonic saline sclerotherapy performed 3-7 days after laser therapy (alexandrite laser at 20 J/cm<sup>2</sup>, single pulsed with a pulse duration of 5 ms) induced an 87% reduction in leg telangiectasia.<sup>6</sup>

Treatment of leg telangiectasia with the alexandrite laser benefited from an optimal pulse duration. Ross et al investigated spot sizes of 3-6 mm and pulse durations of 3-100 ms in 15 patients with Fitzpatrick skin types I-III with telangiectasia ranging from 0.2 to 1.0 mm. The most common treatment site was the thigh, followed by the calf. Mean threshold radiant exposure for closure was 89 J/cm<sup>2</sup>, with an optimal pulse duration of 60 ms, which resulted in clearance of 65% of lesions at 12 weeks after a single treatment. Transient hyperpigmentation occurred in 27% of patients. Increasing the pulse duration beyond 3 ms resulted in an improved epidermal tolerance and decreased the occurrence of purpura. In most cases, the optimal pulse duration, spot size, and radiant exposure results at the 3-week test site visit were determined to be 60 ms, 6 mm, and 89 J/cm<sup>2</sup>, respectively, which produced the best overall combination of vessel improvement, epidermal safety, and absence of purpura and inflammation. Comparison of the average volumetric heat between 6-mm beam diameters of 1064-nm and 755-nm wavelengths in a 0.8-mm-diameter vessel residing 1 mm below the skin surface indicated values of 4.6 J/cm<sup>3</sup> and 9.1 J/cm<sup>3</sup> for the 1064-nm and 755-nm wavelengths, respectively, explaining the superior vessel ablative effects of the

alexandrite laser. Of note, for 755-nm irradiation without the addition of surface cooling, the volumetric heat production in the epidermis is higher than within the vessel.<sup>7</sup>

In a recent study published in 2008, McGill et al<sup>8</sup> investigated the effects of alexandrite, potassium-titanyl-phosphate, and Nd:YAG lasers, and intense pulsed light (IPL) vs additional PDL in 18 patients with previously treated capillary malformations (CM). The alexandrite laser, among all light sources used, induced the highest improvement on the Munsell color chart (GretagMacBeth, New Windsor, NY), which was standardized for observatory and lightening variability with statistical power ( $P = .023$ ), and resulted in fading of the CM in 10 of 18 (55.5%) patients. The alexandrite laser was also the only device that induced a significant reduction in the diameter on videomicroscopy of the treated capillaries ( $P = .009$ ). Thus, the alexandrite laser at 70 J/cm<sup>2</sup> resulted in a reduction of the mean capillary diameter from 60  $\mu\text{m}$  at baseline to 30  $\mu\text{m}$ , followed in efficacy by the alexandrite laser at 50 J/cm<sup>2</sup>, which decreased the mean capillary diameter to 37  $\mu\text{m}$ , and IPL at 34 J/cm<sup>2</sup>, which induced a decrease of the capillary diameter to 36  $\mu\text{m}$ . In conclusion, response to treatment was predicted by the mean pretreatment capillary diameter, with vessels larger than 40  $\mu\text{m}$  being more responsive to therapy. The application of suction increased the diameter of blood vessels up to 2 times their original size. In addition, these vessels were calculated to be displaced toward the skin surface by 1-3  $\mu\text{m}$ .<sup>9</sup> An improved blanching of CM and a reduced purpuric threshold were observed through a 3 times increase in dermal blood volume fraction achieved with the induction of venous stasis by a 100-mm Hg pressure cuff.<sup>10</sup>

A direct comparison of long-pulse PDL with long-pulse alexandrite lasers in the treatment of PWS by Li et al in 11 patients with Fitzpatrick skin types III-IV showed that both lasers were effective in the treatment of PWS, with slightly more hyperpigmentation seen with the alexandrite laser. The alexandrite laser appears to best address the hypertrophic purple PWS, whereas PDL yields better clinical results with the flat pink PWS. Effectiveness of the alexandrite laser in purple hypertrophic PWS may be explained by its combined ability to target deoxyhemoglobin, a deeper penetration, and a higher fluence.<sup>11</sup>

The unique ability of the variable LPA to concomitantly have a better beam penetration than 532-595 lasers and twice the photon absorption by hemoglobin than at 1064 nm led Ross et al<sup>2</sup> to explore its ability to treat facial telangiectasia in fair-skinned patients. Parameters used were a mean fluence of 88 J/cm<sup>2</sup> with a 6-mm spot. Pulse duration varied between 20 and 60 ms. Of 17 patients who completed treatment, 15 underwent a final 12-week follow-up. The average clearance rate across all pulse durations and all vessel diameters was 48% after 1 treatment session at 12 weeks of follow-up. According to the pulse duration, clearance of lesions was achieved in 31% of cases with 3 ms, 35% of cases with 20 ms, 43% of cases with 40 ms, and 32% of cases with 60 ms. Spot-size purpura occurred at only test sites with the 3-ms pulse duration. A good balance between vessel reduction and pain tolerance in skin types I and II using surface cooling was

achieved for vessels 0.4-1.6 mm in diameter. A limitation of treatment of telangiectasia with this laser consists of its bias toward melanin over vascular heating.

## Selective Laser Targeting of Skin Cancers

Theoretic advantages of using lasers in skin cancer consist of the following: less invasiveness, use in locations where surgery can result in anatomic distortion or functional impairment, potential for an excellent cosmetic result, and the possibility of combining targeted laser irradiation or using it as an adjunct to photodynamic therapy (PDT) in patients at high risk of developing skin cancers.<sup>12</sup>

The use of the 585-nm PDL for basal cell carcinomas (BCCs) was driven by their histology, as many BCCs have a feeding microvasculature in the shape of a basketlike capillary plexus consisting of vessels with a luminal diameter of 20  $\mu\text{m}$  or more,<sup>13</sup> corresponding on the surface to the visible telangiectasia. PDL pulsed at 0.45-1.5 ms represents the standard treatment for PWS, telangiectasia, and hemangiomas.<sup>14-16</sup>

As the microvasculature plays an important role in the nutrient support and BCC tumorigenesis,<sup>17</sup> targeting the vascular supply of this tumor is analogous to that obtained by selective vascular microembolization, a practice that is common in treating various tumors.<sup>18</sup> Destruction of the blood vessels within the BCC structure is made on the principle of selective photothermolysis, analogous to the mechanism used by PDL in vascular lesions. Correlating with fluence, PDL penetrance into skin varies from 0.7 to 1.3 mm, which is in the range of the vasculature that feeds a BCC.<sup>19</sup>

In a recent study by Shah et al.,<sup>20</sup> 20 biopsy-proven BCCs were treated with 4 595-nm PDL treatments (energy of 15 J/cm<sup>2</sup>, 3 ms, 7-mm spot size with 10% overlap of pulses, and no cooling). Of these, 91.7% (11/12) of BCCs smaller than 1.5 cm in diameter had a complete response ( $P = .0003$ ), compared with only 16.7% of controls. BCCs larger than 1.5 cm in diameter showed a complete response rate of 25%, compared with 0% in controls ( $P = .2$ ). Tumor histologic types of the complete responders included superficial, nodular, micronodular, and keratinizing. Incompletely responding BCCs still demonstrated a significant reduction in tumor burden after PDL treatment, with residual tumor burden on histologic examination ranging from <1% to 29% of the original clinical tumor size, compared with 13%-68% residual tumor burden for the corresponding controls ( $P = .05$ ). None of the patients developed tumor ulceration or scarring after treatment. The most frequent reaction to treatment was purpura followed by a gray discoloration of the skin, infrequently associating hemorrhagic scaling and crusting, but with no deep skin damage. Smaller BCCs may respond better than the larger lesions secondary to a more-fragile vasculature that is more immature and, therefore, more susceptible to destruction by laser. The conclusion of this study was that PDL is an effective means of reducing tumor burden in pa-

tients with large BCCs and may be considered an alternative therapy in BCCs <1.5 cm in diameter.

The alexandrite laser has also been used for nonmelanoma skin cancer, where high fluences (100 J/cm<sup>2</sup>) and an 8-mm spot were applied to "bulk" heat the tissue. Biopsies showed that vascular structures served as the initial targets from which heat diffused to surrounding localized micronodules of BCC.<sup>21</sup>

## New Topics in Photodynamic Therapy

An attempt to determine whether PDL or IPL can activate protoporphyrin IX (PpIX) in the absence of ambient light and to compare it with the standard therapeutic CW light at a dose lower than that required for clinical AK was made by Strasswimer and Grande.<sup>22</sup> In this study, IPL and flashlamp-pumped PDL were capable of activating PpIX, but pulsed light induced a lesser reaction than a standard CW blue-light source.

The efficacy and safety of PDL as the light source for photoactivation of PpIX to treat Bowen's disease using PDT were assessed by Britton et al.<sup>23</sup> in 17 lesions of Bowen's disease. Treatment was performed with 20% 5-aminolevulinic acid (ALA) under occlusion for 4 hours followed by irradiation with a 585-nm PDL Candela SPLTL-1b device (Candela Corporation, Wayland, MA) with a 7-mm diameter spot at a fluence of 10 J/cm<sup>2</sup>. At 2 months, 8 treatment sites could not be assessed because of loose overlying crusts; removal of these revealed superficial erosions in 7 patients. Of the 17 lesions treated, on follow-up at 1 year, 14 patches (82%) demonstrated complete clinical response, although 1 had required a second treatment. In addition, 2 patients with 3 lesions that needed further therapy refused a second treatment. Prolonged crusting lasting 8 weeks occurred in 8 patches, and prolonged discomfort lasting 6 weeks occurred in 4 patients. PDL appears to be an efficient light source for ALA-PDT treatment of Bowen's disease.

## Cellulite

Treatment of cellulite has largely relied on various "wraps" and massage technologies, sometimes coupled with low-level light and lasers. Results have been modest in most cases. The pathophysiology of cellulite is unclear, and therapies have addressed lymphatic flow, strengthening of the dermis, fat destruction, and lysis of fibrous septae. A recently introduced device uses side-firing laser fibers to lyse fibrous bands that are a contributor to cellulite. DiBernardo<sup>24</sup> evaluated the efficacy, safety, and duration of the clinical benefit associated with a single-treatment pulsed laser that delivered 1440 nm energy to the dermal-hypodermal interface. Subjects received a single treatment with a 1440-nm pulsed laser. Energy was delivered to the subdermal tissue through a fiber designed for targeted delivery of laser energy and enclosed in a cannula. Treatment addressed the thinning dermal layer, hypodermal fat lobules that extend upward into the dermis, and fibrous septae by thermal subcision. Ultrasonography,

skin elasticity measurements, and photographs were conducted at baseline, 1, 3, 6, and 12 months. Mean skin thickness (as shown by ultrasonography) and skin elasticity showed ( $P < .001$ ) increases at each time point. Subjective physician and subject evaluations indicated improvement, high subject satisfaction, and minimal adverse effects.

## Laser Lipolysis and Fat Removal

Selective fat destruction with laser has proven difficult, largely secondary to the depth of fat relative to the penetration depth of the laser. Three wavelengths, 915 nm, 1210 nm, and 1720 nm, show favorable ratios of light absorption relative to water; however, the ratios are less than 1.5, such that selectivity is marginal. Surface cooling improves the likelihood of achieving a temperature gradient between superficial water (dermis) and subcutaneous fat.<sup>25,26</sup> Articles reporting fat destruction showed that long (several seconds) irradiation times are required for adequate fat heating; the long heating times and inevitable heating of tissue water are associated with considerable pain.<sup>27</sup>

The Food and Drug Administration approval in October 2006 of a 1064-nm Nd:YAG laser lipolysis system (Deka, Cynosure, Westford, MA) triggered an influx of manufacturers to market Nd:YAG and diode devices emitting laser radiation between 920 nm and 1320 nm, as advantages were claimed for each of the frequencies. A combination of frequencies (980-nm diode and 1064-nm Nd:YAG laser) was used by Mordon et al<sup>28</sup> in 2007 in a mathematical model that suggested for the first time that heat generated by the interaction of laser light energy with the tissue rather than the biophysical effects of a particular wavelength produced fat destruction, which facilitated a focused approach in developing the efficiency of lipolysis devices. Skin tightening appears to occur at dermal temperatures of 48°C–50°C without inducing burning injury to the epidermis. Corresponding external temperatures that balance safety and a good lipolytic effect were found to be in the range of 38°C–41°C. However, a search for the optimal laser frequency in inducing lipolysis and/or skin tightening, including 924, 968, 980, 1064, 1319, 1320, 1344, and 1440 nm, has not identified a single optimal frequency that would achieve simultaneously both goals and would satisfy both efficiency and safety criteria. For example, irradiation of fat tissue with 924 nm has the highest selectivity for melting of adipose cells, but not as good of a skin-tightening effect.<sup>29</sup>

## Acne

Destruction of the sebaceous glands should deprive the acne-prone follicle of the fuel that feeds the acne fire. Like fat, sebum enjoys preferential light absorption at 915 nm, 1210 nm, and 1720 nm. The more superficial location of the glands compared with the subcutaneous fat layer permits a more favorable scenario for selective heating. With optimized parameters, selective sebaceous gland heating can be achieved. Future trials should uncover those settings that create a practical device for “sebum”-based acne clearing.

PDT in acne continues to be improved. Drawbacks to ther-

apy include long incubation times and phototoxicity. Various methods have been used to decrease these side effects, many of which are from epidermal PpIX formation. Cooling the epidermis can suppress both singlet O<sub>2</sub> formation as well as suppress the conversion of ALA to PpIX.


Another way to suppress epidermal damage is to inhibit surface fluorescence by photobleaching the epidermis using low-power density blue light. In this way, PpIX is converted to photoproducts. Sakamoto et al<sup>30</sup> introduced this new concept with ALA to enhance the ratio of sebaceous gland to epidermal fluorescence and phototoxicity. They discovered that low-level light exposure during the period of ALA metabolism prevents accumulation of porphyrins and can be used to selectively inhibit epidermal porphyrins. Because light prevents accumulation of the photosensitizer, they called this phenomenon “photoinhibition” of PDT or “i-PDT.” They studied PpIX in cultured human keratinocytes, and in vivo in Yorkshire swine, by measuring porphyrin accumulation, cell lethality, and inflammatory responses when inhibitory red (635 nm) or blue (420 nm) light was delivered during metabolism after topical ALA application. Subsequent exposure to high-fluence red light was then used to activate a PDT reaction. i-PDT was compared split-face with conventional PDT in a patient with recalcitrant acne. They found, in an irradiance-dependent manner, that low threshold levels of blue light (60–100 μW/cm<sup>2</sup>) suppressed porphyrin accumulation in vitro and in vivo, with a corresponding decrease in inflammation after PDT. i-PDT produced much less inflammation, yet a similar benefit in deeper targets compared with conventional PDT.

## Pixelated Radiofrequency

The increasing use of radiofrequency (RF) devices as laser “surrogates” is expected. RF devices are typically less expensive to manufacture than their laser counterparts and can perform some tasks as well as light. They can only act as substitutes for laser where water is the target, as RF devices offer none of the selective absorption for HgB and melanin as do wavelength-specific lasers. We recently studied a pixelated RF device that creates plasmas at the skin surface (Fig. 1) (Pixel RF, Alma lasers, Buffalo Grove, IL). The microwounds are similar to that produced by fractional CO<sub>2</sub> lasers (Fig. 2). The device is equipped with a roller that delivers wounds at a specific pitch. Multiple passes are delivered to achieve a final wound density sufficient to improve acne scarring, wrinkles, and/or striae (Fig. 3).

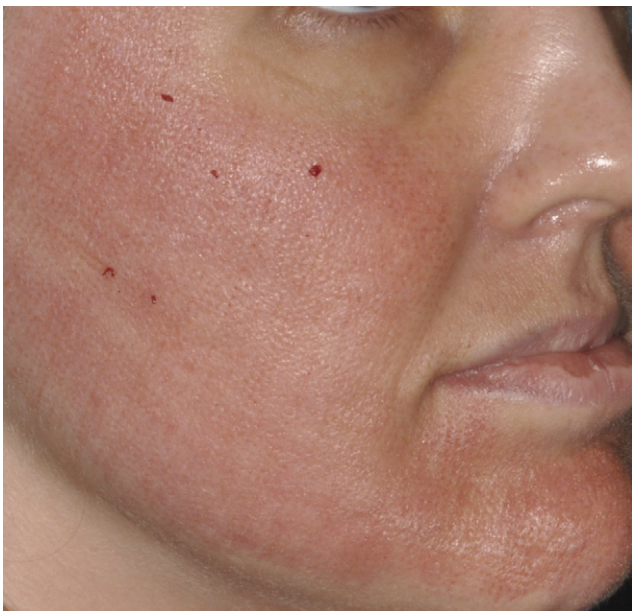## Lasers for Infections

Recent evidence supports a role for lasers in certain infections, most notably onychomycosis.<sup>31</sup> Studies have shown that 42.5°C for 2 minutes is sufficient to inactivate *T rubrum* and other pathologic fungi. However, much of this work was done in culture plates and might not be extrapolated to a thickened dystrophic nail. Both long-pulsed and Q switch Nd:YAG lasers, as well as 1320-nm lasers, have been applied to nails.<sup>32</sup> Typically, sessions are carried out every 1–4 months, and nails are treated to a point

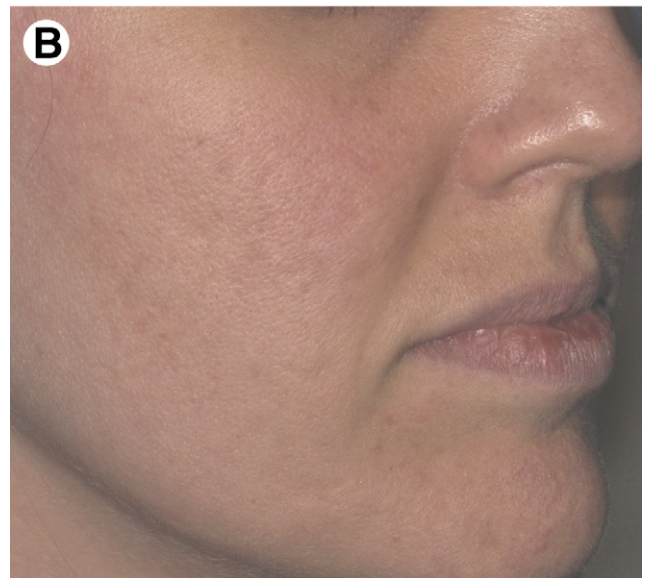
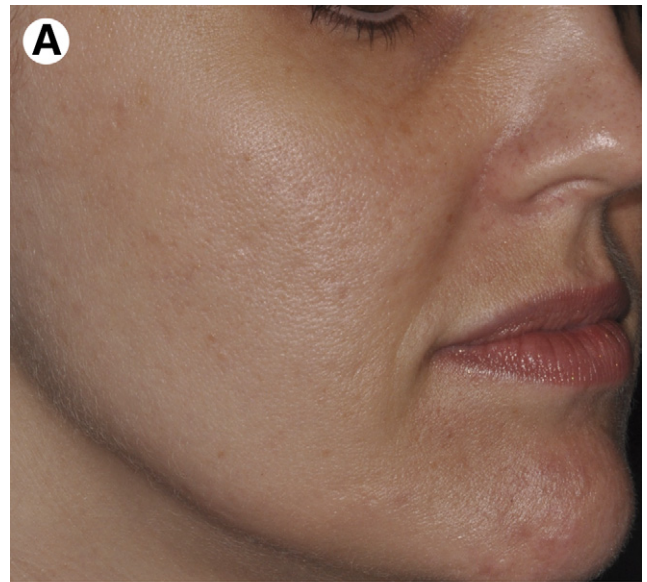

**Figure 1** Roller RF device.

where the patient reports a “warm” sensation. Another laser uses 870 nm and 930 nm light.<sup>33</sup> They found that after 4- and 2-minute exposures (in the same office visit) which were carried out 4 times at roughly monthly intervals, 75% of the nail cultures had cleared. They used infrared (IR) thermometers to maintain temperature (T) at 102°F (39°C) at a laser power density of 1 W/cm<sup>2</sup>. Other lasers have been applied, but no published peer-reviewed studies compare laser with conventional medical approaches. One popular system is the PinPointe laser, a device that uses 1064 nm to gently heat the nails. In the



**Figure 2** Patient just after treatment with roller RF device—note microwounds about 200  $\mu$ m in diameter.



**Figure 3** (A) Pretreatment RF pixel acne scar. (B) 3 months after 1 treatment.

future, expect to see other light-based technologies that inactivate fungus and bacteria through photothermal or photochemical means.

### Combining Medications and Laser

Nelson et al<sup>34</sup> have examined the role of angiogenesis-inhibiting drugs. They noted that PDL is the treatment of choice for PWS, but that in many cases, lesions remain resistant to laser treatment. They theorized that low therapeutic efficacy might be caused by revascularization of photocoagulated blood vessels owing to angiogenesis associated with the normal wound-healing response. Rapamycin, an inhibitor of mammalian target of rapamycin, effectively inhibits the growth of pathologic blood vessels. They developed a transgenic mouse model of pathologic angiogenesis with inducible overexpression of activated

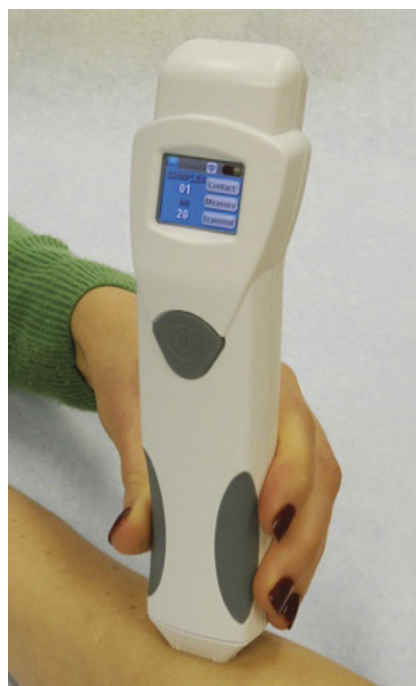protein kinase B (Akt) in endothelial cells (myrAkt mice). Pathologic vessels in the skin of myrAkt mice were photo-coagulated with laser pulses. One day after laser treatment, animals were treated once a day with 5% topical dimethyl sulfoxide or 5% topical rapamycin for up to 22 days, at which time they were sacrificed for analysis by histology and immunofluorescent stains for CD31 (blood vessels) and CD45 (leukocytes). Treatment of myrAkt-induced pathologic blood vessels with laser pulses plus topical dimethyl sulfoxide resulted in the reformation of abnormal vessels 22 days after laser treatment. However, treatment with laser plus topical rapamycin completely blocked the reformation of the abnormal vessels after laser ablation, as seen on H&E (hematoxylin and eosin) and CD31 stains.

## Enhanced Drug Delivery with Fractional Technologies

The stratum corneum poses a formidable barrier to drug penetration through the skin. Techniques to enhance drug delivery include occlusion, iontophoresis, barrier disrupters, tape stripping, Q-switched laser with a black dye, and microdermabrasion technologies. Recently a group reported enhanced drug delivery through fractional wounds with PDT. Present incubation times, particularly for nonmelanoma skin cancer, range from 3 to 12 hours for pan fluorescence of PpIX after ALA. On the other hand, after fractional wounding, even with surface densities of as little as 5%, studies showed rapid drug uptake and enhanced drug penetration. They showed orders of magnitude increases in fluorescence as deep as 2 mm below the surface.<sup>35-37</sup> Likewise, we have observed a similar dramatic increase in drug uptake and PpIX formation after fractional priming of the skin before ALA application (Fig. 4).

## Real-time Temperature and Pigment Measurements

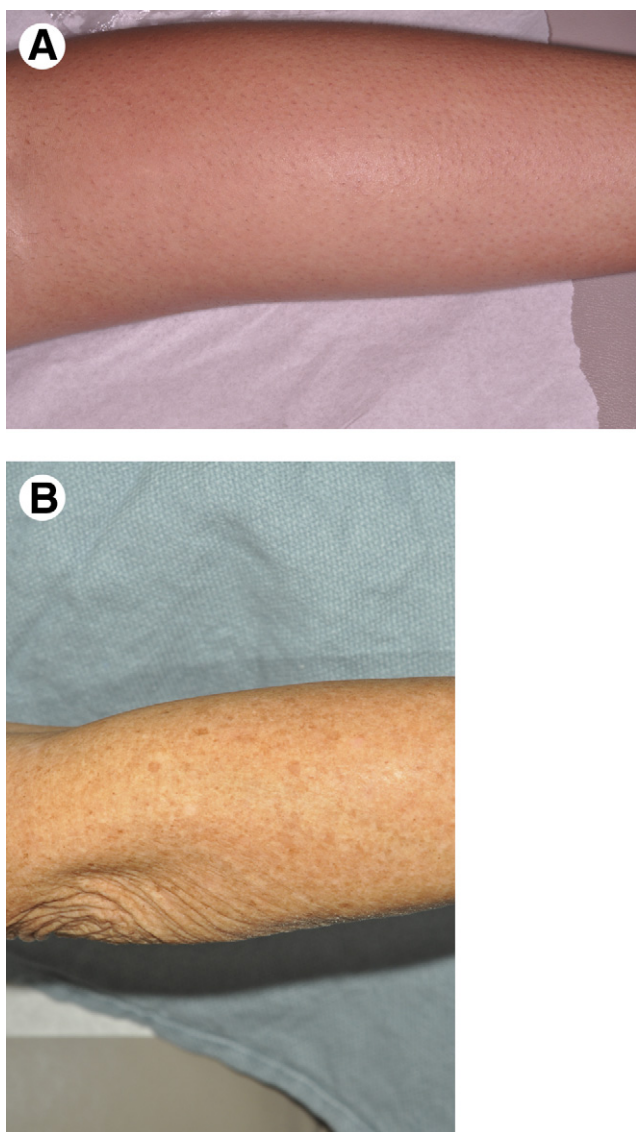
Objective tools to examine the skin condition are other additions to the laser and IPL arsenal. These measurements should aid in selecting optimal settings for wavelength ranges where the epidermis is heated. For example, most laser surgeons concede that “eyeball” assessment of background epidermal melanin content is inconsistent and often inaccurate. Overestimation leads to unnecessarily conservative settings and disappointing results; underestimation leads to excessive settings that can result in vesiculation and even scarring. In our daily practice, we evaluated the predictive value of real-time Melanin Index (MI) measurements (Skintel, Palomar Medical, Burlington, MA) for determining appropriate IPL treatment settings across 5 treatment centers. The goal was to identify a starting point fluence setting that was at or just below the optimal treatment settings. Because skin tolerance is predicted to be related to melanin content, then real-time measurement of melanin should make it possible to accurately predict appropriate treatment settings. Pulse width and



**Figure 4** Skintel pigment meter in action—the device reports a value between 10 and 100.

fluence settings (selected based on eyeball assessment of experienced operators) collected during patient treatments were compared with MI-determined presets that were derived from maximum tolerated fluence measured on more than 100 patients. A 3-wavelength backscattering reflectometer was used for MI values, which transmitted settings to the base and which then provided preset fluence values based on selection of pulse width (Fig. 5). Additionally, in more than 30 patients, test spots were performed in affected areas at the MI-determined presets as well as at fluences 2 J/cm<sup>2</sup> below and above the preset. The spots were evaluated 1 hour after irradiation for optimized visual end points (darkening of pigmented lesions and vessel clearing). We found that 70%-90% of the patient treatment settings (n = 85) were at or just above (0-4 J/cm<sup>2</sup>) the suggested starting test spot fluence setting, as predicted based on MI measured within the treatment area. Only 4% of the cases had the starting point settings above the treatment settings (all within 4 J/cm<sup>2</sup>). Test spots in affected skin likewise showed that across the range of reflectometer-guided settings, no settings were determined to be unsafe; moreover, the settings were within 20% of settings the provider would have chosen without reflectometer guidance. Individuals with different Fitzpatrick skin type, but with similar melanin content, were found to have similar skin tolerance to IPL treatment (Figs. 6A and B). We concluded that when used appropriately, MI-based guidance has the potential to reduce risk of complications, particularly in less-experienced operators.

Another device that might be commercially available in the future is a real-time surface T-measuring device to guide safe settings. Unlike the inexpensive “hardware store” IR cameras that can measure T only over long times (seconds), this de-



**Figure 5** (A) Untanned type V patient with meter reading of 30. (B) Tanned type III patient with same reading.

vice can measure  $T$  with response times as short as  $1 \mu\text{s}$ , allowing one to accurately show the peak  $T$  even for pulsed lasers. This type of device has been studied by Majaron et al.<sup>38</sup> They found that despite the application of dynamic cooling, the efficacy and safety of cutaneous laser treatments are often compromised by nonselective absorption of epidermal melanin. The authors examined pulsed photothermal radiometric (PPTR) temperature depth profiling for prediction of maximal safe radiant exposure for human skin on an individual basis.

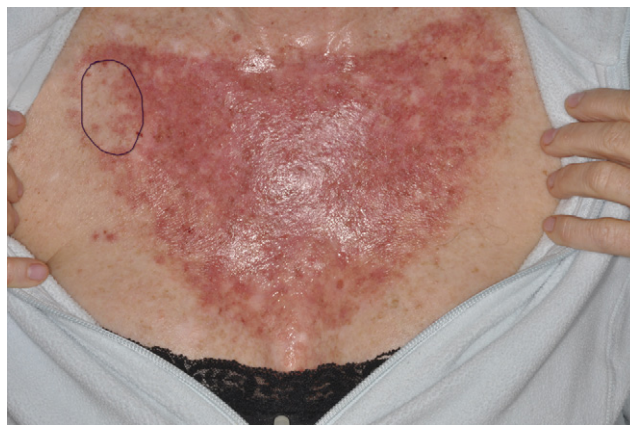Diagnostic PPTR measurements were performed on 326 distinct spots on the extremities of 13 healthy volunteers using 3-ms laser pulses at 755 nm and  $6 \text{ J/cm}^2$ . From these radiometric signals, the respective laser-induced temperature depth profiles in skin were reconstructed using a custom iterative algorithm with adaptive regularization. The same test spots were irradiated with the same laser at radiant exposures from 10 to  $90 \text{ J/cm}^2$  with application of

cryogen spray precooling at constant settings. The resulting adverse effects were quantified by blind scoring and correlated with various characteristics of the corresponding PPTR temperature profiles. The area under the epidermal part of the reconstructed temperature profiles (representing the surface density of the laser energy deposited in the epidermis) allowed for a prediction of individual epidermal damage threshold across a wide range of tested skin phototypes (I–IV).<sup>39</sup>

Because the surface  $T$  increase and epidermal risks have been shown to increase roughly proportionally to the epidermal melanin content, the need for a real-time  $T$  assessment (over a less-expensive simple melanin measurement) is unclear. Future studies might nonetheless show that built-in  $T$  meters might not only improve safety but also report  $T$  end points that are associated with efficacy. Noninvasive imaging techniques might also report subsurface changes (ie, vascular occlusion) not observable from the surface (such as in the treatment of PWS). Increasingly we might see “bedside” technologies that enhance our ability to treat patients with fewer visits. In other words, rather than treat by recipe, we would treat exclusively end point.<sup>40</sup> Many other noninvasive technologies have entered this arena, including confocal microscopy, multiphoton microscopy, and optical coherence tomography.<sup>41</sup>

## Emergence of Home Use Devices

The increasing miniaturization of devices has allowed for home use in a range of applications. Multiple home hair-removal devices are available as are light-emitting diode panels for acne. Any home-based therapy must overcome eye safety issues. Typically this is achieved by not allowing the laser to fire unless in contact with the skin. With “home” fractional lasers, overtreatment risks are decreased by time limiting the number of total pulses in any given time period. Leyden et al<sup>42</sup> evaluated the safety and efficacy of a novel



**Figure 6** Patient 5 days after ALA PDT after pretreatment with fractional erbium laser. The reaction occurred after only a 30-minute incubation period—note the circled area was not pretreated with the fractional laser and shows little response.

nonablative fractional laser device designed for self-use at home (Palo Via, Palomar Medical). The trials comprised 2 studies (Pilot and Pivotal). Devices (1410 nm) were issued to the subjects for self-application at home to treat periorbital wrinkles. Both studies included 2 phases: active treatment phase (daily treatments) and maintenance phase (twice-weekly treatments). Subjects were followed up to 6 months after completion of the active phase. All subjects were able to use the devices after reading the written instructions for use. Treatment was well tolerated with good protocol compliance. Blinded evaluations revealed improvement of the Fitzpatrick wrinkle score in 90% of subjects at the end of the active phase and in 79% of subjects at the end of the maintenance phase, with a high degree of grading uniformity between the evaluators.

## Enhanced Beam Penetration Tools

Optical clearing, either through specially designed compression handpieces or through chemical agents, has been used to enhance light penetration in the turbid dermis. These approaches have been shown to enhance clearing of tattoos and vascular lesions. A recent article examined optical clearing with both glycerol (one optical clearing agent) and compression.<sup>43</sup> In porcine skin, they examined images through a range of skin thicknesses. They found that both optical clearing agents and compression enhance light transmission but that the compression methods outperformed chemical agents as far as image resolution. The compression method resulted in tissue thickness reductions. They used small compressive windows compared with those used in previous studies. Another study examined optical compression pins to heat the dermis and hypodermis. Zelickson et al<sup>44</sup> studied such a device where 1540-nm and 1208-nm laser microbeams (mb) are coaligned with optical pins to provide skin compression that minimizes epidermal injury while treating deeper skin layers. The fractional devices were characterized *ex vivo* and clinically. The 1540-nm device delivered up to 70 mJ/mb in an array of 49 pyramid-shaped pins (XD optic, Palomar Medical Technologies, Inc, Burlington, MA). The 1208-nm prototype consisted of a 5-pin array delivering 4 W/mb in 5-20 seconds. Porcine skin was treated *ex vivo*. Abdominal skin of 2 subjects was treated and biopsy was performed before abdominoplasty. Coagulation profiles were assessed with cell viability staining. Effects of compression were assessed clinically by measuring the size of pigmented spots on volar forearms or back 2 days posttreatment with the 1540-nm device and by measuring skin transmission through the finger webs with a 1450-nm test device. Medial or lateral thighs of 2 subjects were treated with the 1208-nm device under local anesthesia and evaluated 3 weeks post-treatment. In vivo skin transmission of 1540-nm light increased, and the diameters of the 1540 spots decreased with compression time. The 1540-nm device provided deeper coagulation to

1.5-mm depths and less epidermal injury than without compression. The depths of the 1208-nm device reached below 3 mm into the hypodermis with papillary dermis preservation. Clinically palpable indurations persisted up to 3 weeks post-treatment and resolved with no adverse side effects.

Another potentially useful development is the use of laser “holes” to allow for deeper penetration of light. This approach relies on sequential pulsing, first with an ablative wavelength followed by a second laser that requires this kind of bypass for deeper penetration. Kositratna and Manstein<sup>45</sup> reported such a device where they applied focused CO<sub>2</sub> laser radiation to create a “gateway” for transdermal light delivery. They investigated a novel approach to overcome this barrier by creating CO<sub>2</sub> laser-assisted micro channels as optical gateways for laser radiation. They used full-thickness human skin samples procured as discarded tissue from abdominal surgery for the experiments. A focused CO<sub>2</sub> laser beam of approximately 1 J was used to create the gateway. A second CO<sub>2</sub> laser pulse of substantially lower energy was delivered a few seconds later. The effectiveness of the gateway was assessed by measuring the ratio of energy that was delivered by this subsequent laser pulse through the gateway. The dermal thickness was approximately 2.5 mm, and the CO<sub>2</sub> laser-created gateways exhibited an entry diameter of up to approximately 400 μm. More than 60% of the entry energy was delivered through the gateway by the second pulse. They concluded that laser-created micro channels can be used as a novel gateway to deliver laser radiation to deep layers of the skin.

## TRASER

A nonlaser device that might evolve commercially is the TRASER (total reflection amplification of spontaneous emission of radiation). Morgan Gustavsson and Christopher Zachary introduced this concept at the 2011 Controversies in Lasers meeting in Asheville NC, August 11-13, 2011. This device uses total internal reflection to “amplify” light vs a resonator and a laser rod. The potential advantages are lower manufacturing costs, increased versatility, and enhanced power levels vs similarly configured lasers. As Rox Anderson,<sup>46</sup> has noted, laser is really just a convenient source for photons, and other sources (ie, IPL) and TRASER might prove equally adept in dermatology. Like all physical processes, LASER, despite the acronym, only “amplifies” radiation within the confines of conservation of energy. The greatest advantages of laser (ie, monochromaticity) and collimation are not necessary conditions for successful cutaneous light tissue interactions. Chromophores such as HgB and melanin absorb many wavelengths, and collimation and focusability are mostly helpful with fiber-based interstitial applications.

## Conclusions

The rapid advances in tissue optics, electronics, and engineering should increase the role of energy-based technolo-



gies in the dermatology arena. Noninvasive imaging devices will be deployed alongside our high-energy lasers where presumably the feedback from the former will optimize treatment algorithms for the latter. One day, for example, a dermatologist might perform an optical biopsy to diagnose a BCC followed by same-day PDT treatment. In another room, a provider will be guided by a skin assessment meter to select optimal settings for laser treatment of a photodamaged chest. All of this will occur as technology costs decrease for noninvasive imaging and as we witness a progressive miniaturization in device dimensions.

## References

1. Trafeli JP, Kwan JM, Meehan KJ, et al: Use of a long-pulse alexandrite laser in the treatment of superficial pigmented lesions. *Dermatol Surg* 33:1477-1482, 2007
2. Ross EV, Meehan KJ, Domankevitz Y, et al: Use of a variable long-pulse alexandrite laser in the treatment of facial telangiectasia. *Dermatol Surg* 36:470-474, 2010
3. Rubin IK, Farinelli WA, Doukas A, et al: Optimal wavelengths for vein-selective photothermolysis. *Lasers Surg Med* 44:152-157, 2012
4. Kamel M: Scars after laser alexandrite treatment in port wine stains resistant. *Lasers Surg Med Suppl* 42(Suppl 22):39, 2010
5. McGill DJ, MacKay IR: The treatment of intra-oral venous vascular malformations using the alexandrite laser. *Plast Reconstr Surg* 119:1962-1964, 2007
6. McDaniel H, Ash K, Lord J, et al: Laser therapy of spider leg veins: Clinical evaluation of a new long pulsed alexandrite laser. *Dermatol Surg* 25:52-58, 1999
7. Ross EV, Meehan KJ, Gilbert S, et al: Optimal pulse durations for the treatment of leg telangiectasias with an alexandrite laser. *Lasers Surg Med* 41:104-109, 2009
8. McGill DJ, MacLaren W, Mackay IR: A direct comparison of pulsed dye, alexandrite, KTP and Nd: YAG lasers and IPL in patients with previously treated capillary malformations. *Lasers Surg Med* 40:390-398, 2008
9. Childers MA, Franco W, Nelson JS, et al: Laser surgery of port wine stains using local vacuum pressure: Changes in skin morphology and optical properties (part I). *Lasers Surg Med* 39:108-117, 2007
10. Svaasand LO, Aguilar G, Viator JA, et al: Increase of dermal blood volume fraction reduces the threshold for laser-induced purpura: Implications for port wine stain laser treatment. *Lasers Surg Med* 34:182-188, 2004
11. Li L, Kono T, Groff WF, et al: Comparison study of a long-pulse pulsed dye laser and a long-pulse pulsed alexandrite laser in the treatment of port wine stains. *J Cosmet Laser Ther* 10:12-15, 2008
12. Choudhary S, Tang J, Elsaie ML, et al: Lasers in the treatment of non-melanoma skin cancer. *Lasers in the treatment of nonmelanoma skin cancer. Dermatol Surg* 37:409-425, 2011
13. Grunt TW, Lametschwandtner A, Staindl O: The vascular pattern of basal cell tumors: Light microscopy and scanning electron microscopic study on vascular corrosion casts. *Microvasc Res* 29:371-386, 1985
14. Jasim ZF, Woo WK, Handley JM: Long-pulsed (6 ms) pulsed dye laser treatment of rosacea-associated telangiectasia using subpurpuric clinical threshold. *Dermatol Surg* 31:37-40, 2004
15. Katugampola GA, Lanigan SW: Five years' experience of treating port wine stains with the flashlamp-pumped pulsed dye laser. *Br J Dermatol* 137:750-754, 1997
16. Greve B, Raulin C: Prospective study of port wine stain treatment with dye laser: Comparison of two wavelengths (585 nm vs. 595 nm) and two pulse durations (0.5 milliseconds vs. 20 milliseconds). *Lasers Surg Med* 34:168-173, 2004
17. Chen GS, Yu HS, Lan CC, et al: CXC chemokine receptor CXCR4 expression enhances tumorigenesis and angiogenesis of basal cell carcinoma. *Br J Dermatol* 154:910-918, 2006
18. Schwarz RE, Abou-Alfa GK, Geschwind JF, et al: Nonoperative therapies for combined modality treatment of hepatocellular cancer: Expert consensus statement. *HPB (Oxford)* 12:313-320, 2010
19. Pikkula BM, Chang DW, Nelson JS, et al: Comparison of 585 and 595 nm laser-induced vascular response of normal in vivo human skin. *Lasers Surg Med* 36:117-123, 2005
20. Shah SM, Konnikov N, Duncan LM, et al: The effect of 595 nm pulsed dye laser on superficial and nodular basal cell carcinomas. *Lasers Surg Med* 41:417-422, 2009
21. Ibrahim OA, Sakamoto FH, Tannous Z, et al: 755 nm alexandrite laser for the reduction of tumor burden in basal cell Nevus syndrome. *Lasers Surg Med* 43:68-71, 2011
22. Strasswimmer J, Grande DJ: Do pulsed lasers produce an effective photodynamic therapy response? *Lasers Surg Med* 38:22-25, 2006
23. Britton JE, Goulden V, Stables G, et al: Investigation of the use of the pulsed dye laser in the treatment of Bowen's disease using 5-aminolaevulinic acid phototherapy. *Br J Dermatol* 153:780-784, 2005
24. DiBernardo BE: Treatment of cellulite using a 1440-nm pulsed laser with one-year follow-up. *Aesthet Surg J* 31:328-341, 2011
25. Alexander VV, Ke K, Xu Z, et al: Photothermolysis of sebaceous glands in human skin ex vivo with a 1,708 nm Raman fiber laser and contact cooling. *Lasers Surg Med* 43:470-480, 2011
26. Anderson RR, Farinelli W, Laubach H, et al: Selective photothermolysis of lipid-rich tissues: A free electron laser study. *Lasers Surg Med* 38:913-919, 2006
27. Wanner M, Avram M, Gagnon D, et al: Effects of non-invasive, 1,210 nm laser exposure on adipose tissue: Results of a human pilot study. *Lasers Surg Med* 4:401-407, 2009
28. Mordon SR, Wassmer B, Reynaud JP, et al: Mathematical modeling of laser lipolysis. *Biomed Eng Online* 7:10, 2008
29. Parlette EC, Kaminer ME: Laser-assisted liposuction: Here's the skinny. *Semin Cutan Med Surg* 27:259-263, 2008
30. Sakamoto FH, Doukas AG, Farinelli WA, et al: Introduction of I-PDT: A new phenomenon able to reduce side-effects of photodynamic therapy (PDT) with Ala and Ala Derivatives. *Lasers Surg Med* 42 suppl 22 (abstract):30, 2010
31. Bornstein E, Hermans W, Gridley S, et al: Near-infrared photoinactivation of bacteria and fungi at physiologic temperatures. *Photochem Photobiol* 85:1364-1374, 2009
32. Hochman LG: Laser treatment of onychomycosis using a novel 0.65-millisecond pulsed Nd: YAG 1064-nm laser. *J Cosmet Laser Ther* 13:2-5, 2011
33. Landsman AS, Robbins AH, Angelini PF, et al: Treatment of mild, moderate, and severe onychomycosis using 870- and 930-nm light exposure. *J Am Podiatr Med Assoc* 100:166-177, 2010
34. Nelson JS, Jia W, Phung TL, et al: Observations on enhanced port wine stain blanching induced by combined pulsed dye laser and rapamycin administration. *Lasers Surg Med* 43:939-942, 2011
35. Togsverd-Bo K, Haak CS, Thaysen-Petersen D, et al: Intensified photodynamic therapy of actinic keratoses with fractional CO<sub>2</sub> laser—A randomized clinical trial. *Br J Dermatol* 2012, Epub ahead of print
36. Haedersdal M, Togsverd-Bo K, Paasch U: Case reports on the potential of fractional laser-assisted photodynamic therapy for basal cell carcinoma. *Lasers Med Sci* (in press)
37. Haedersdal M, Katsnelson J, Sakamoto FH, et al: Enhanced uptake and photoactivation of topical methyl aminolevulinic acid after fractional CO<sub>2</sub> laser pretreatment. *Lasers Surg Med* 43:804-813, 2011
38. Majaron B, Milanic M, Jia W, et al: Prediction of the maximal safe laser radiant exposure on an individual patient basis based on photothermal temperature profiling in human skin. *Lasers Surg Med* 43 Suppl 23 (abstract):917, 2011
39. Verkruysse W, Jia W, Franco W, et al: Infrared measurement of human skin temperature to predict the individual maximum safe radiant exposure (IMSRE). *Lasers Surg Med* 39:757-766, 2007
40. Bazant-Hegemark F, Meglinski I, Kandamany N, et al: Optical coherence tomography: A potential tool for unsupervised prediction of treatment response for port-wine stains. *Photodiagnosis Photodyn Ther* 5:191-197, 2011

41. Tsai TH, Jee SH, Chan JY, et al: Visualizing laser-skin interaction in vivo by multiphoton microscopy. *J Biomed Opt* 14:024034, 2009
42. Leyden J, Stephens T: Multi-center clinical trials of home-use non-ablative fractional laser device for wrinkle reduction. *Lasers Surg Med* 42(suppl 22):34, 2010
43. Izquierdo-Román A, Vogt WC, Hyacinth L, et al: Mechanical tissue optical clearing technique increases imaging resolution and contrast through ex vivo porcine skin. *Lasers Surg Med* 43:814-823, 2011
44. Zelickson B, Walgrave S, Wallander I, et al: Treatment of the dermis and hypodermis junction with water and fat selective laser wavelengths using optical compression pins. *Lasers Surg Med* 43 (suppl):927, 2011
45. Kositratna G, Manstein D: Focused CO<sub>2</sub> laser radiation to create a gateway for transdermal light delivery. *Lasers Surg Med* 42(suppl 22): 28, 2010
46. Anderson R: Laser tissue interactions, in Goldman M, Fitzpatrick R (eds): *Cutaneous Laser Surgery-The Art and Science of Selective Photothermolysis*. St Louis, MO, Mosby, 1994, pp 3-5